

FLORA AND FAUNA

2015 Vol. 21 No. 2 PP 260-264

ISSN 0971 - 6920

STUDIES ON HISTO-PATHOLOGICAL CHANGES IN THE KIDNEY AND INTESTINE OF *HETEROPNEUSTES FOSSILIS* (BLOCH) UNDER BAYRUSIL EXPOSURE.

MD. NOOR ALAM AND VIJAYA LAKSHMI

University Department of Zoology,
Vinoba Bhave University,
HAZARIBAG - 825301, (JHARKHAND), INDIA

Received : 25.8.15; **Accepted** : 21.10.15

ABSTRACT

The present study deals with the toxic effect of an organo - phosphate pesticide, Bayrusil on the Kidney and intestine of an air-breathing fish, *Heteropneustes fossilis* (Bloch). Shrinkage of glomeruli, formation of narrow spaces in the Bowman's capsule, flattening of the cells of renal epithelium in the kidney mass and disruption of serosal layer, loose texture of circular and longitudinal muscle, rupture of intestinal villi at some places were some of the histo-pathological changes in the Kidney and intestine of the test fish under bayrusil exposure.

Figures : 04

References : 25

Table : 00

KEY WORDS : Bayrusil, *H. fossilis* kidney, Histopathology.

Introduction

Next to air water is an important component of life supporting system. But these days industrial growth, rapid urbanisation, heavy dependence of agro-chemicals in the crop-field has put severe environmental stress resulting in higher level of toxicity in the water bodies. Apart from their intended effects, many of these chemicals affect the non-target organisms including fishes^{1,3,4,7,8}. Once the chemicals are discharged into the water bodies, the toxins are incorporated in to the bodies of the fish, adversely affecting the physiology histology and other functions of the body^{11,15,18,19,24}. In the present investigation, an attempt has been made to assess the toxic effects of an organo-phosphate pesticide, Bayrusil on the Kidney and intestine of an air-breathing fish, *Heteropneustes Fossilis* (bloch)

Materials and Methods

Live specimens of *Heteropneustes fossilis* were collected from local fresh water ponds and brought to the laboratory. They were disinfected with 0.1 % KMnO₄ solution to avoid dermal infection. The fishes were allowed acclimatization to the laboratory condition for a period of 15 days and were fed with fish food and rice bran.

To study the toxic effect of the agro-chemical

on the internal organs like kidney and Intestine, the test fish were subjected to LC₅₀ concentration of the pesticide in a glass container chronically for a period of 30 days. Fish specimens showing signs of distress were picked up and dissected out, their kidney and intestine were taken out, cut in to pieces and transferred to Bouin's fixative. Paraffin sections were prepared and the slides were stained with haematoxylin - eosin. The slides were thoroughly examined for revelation of histo- pathological lesions. Also, selected parallel sections of the tissues of control specimens were taken and were included in microphotography for getting comparative idea of the results on the effects of the treatment.

Results and Discussion

Exposure of the test fish in LC₅₀ concentration of the pesticide caused histo pathological lesions in the internal organs in varied magnitude.

The kidney of the exposed fish showed signs of damages in its normal structure. Shrinkage of glomeruli and tubular degeneration took place. The renal peritoneum was partially fragmented (Fig.1). On further exposure of the fish specimens in the toxic media, the lesions were more serious. There was formation of gap between the glomerular

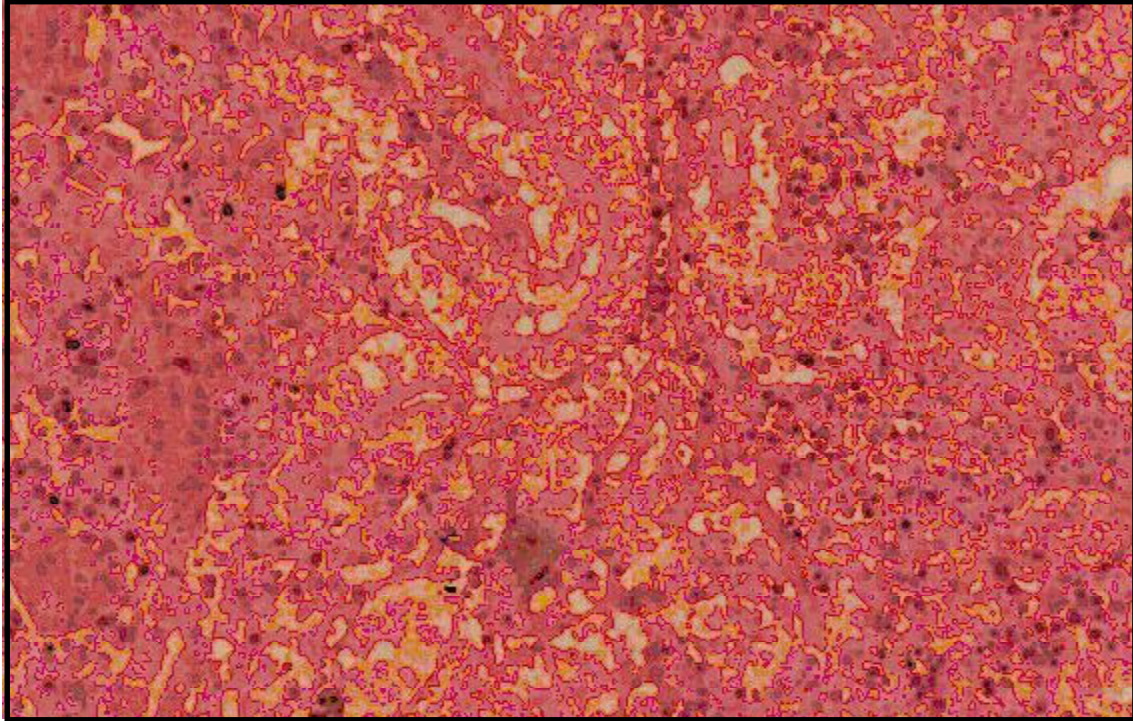


Fig. 1 : Photomicrograph of the section of normal kidney of *H. fossilis*, Haematoxylin- Eosin X400.

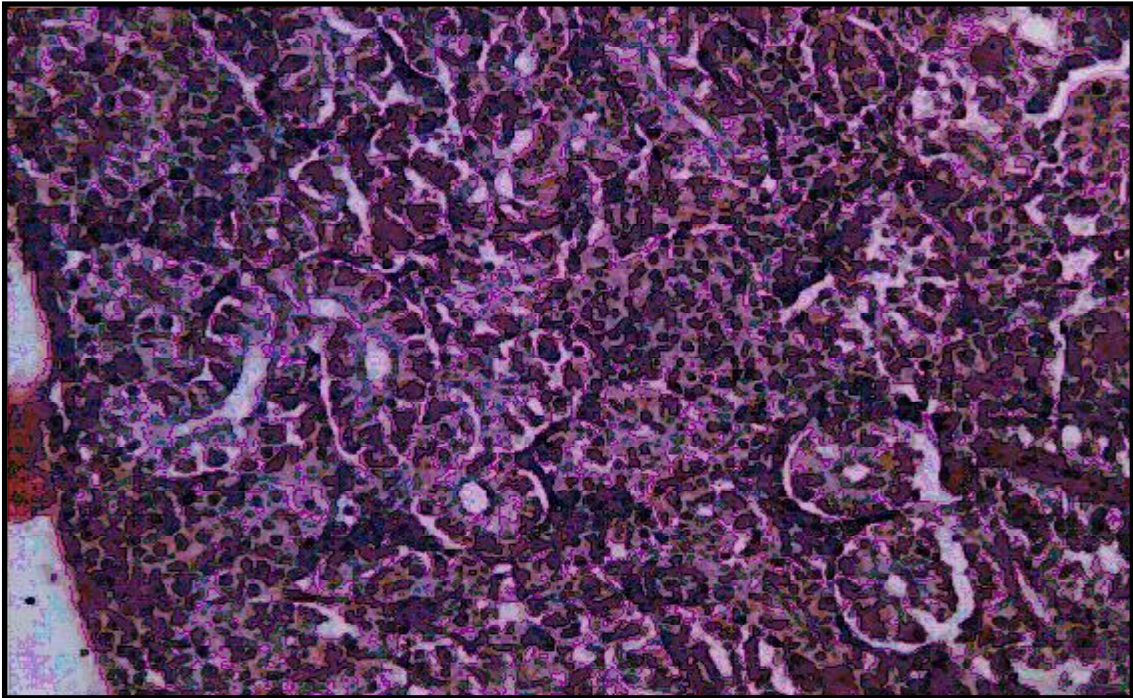


Fig. 2 : Microphotograph of the section of kidney of bayrusil treated *H. fossilis*, for 4 weeks exposure showing harmful effects.

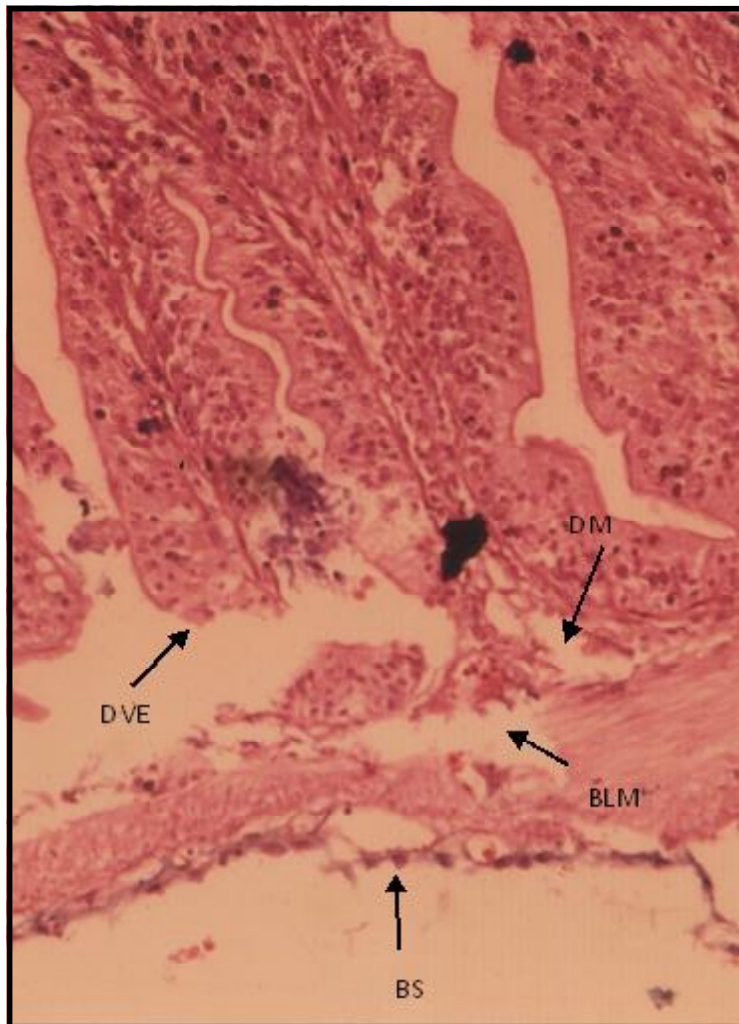


Fig. 3 : Microphotograph of the section of intestine of bayrusil exposed *H. fossilis*, for 2 weeks showing damages. BS=Broken serosa, DVE=Degenerated Villus epithelium, DM=Dissolved Mucosa, BLM= Broken Longitudinal Muscles, Haematoxylin-Eosin X 400.

capsule and its tuft. The nuclei of the cells were slightly displaced towards the periphery. There was destruction and compression in the uriniferous tubules (Fig.2). All these lesions developed in the kidney mass due to the toxic exposure were indicative of setback in the excretory and osmoregulatory capacity of the kidney.

Similar changes in the histological structure of the kidney of other fish have also been observed by other workers,^{4,5, 10, 13, 16, 17, 20, 23, 25.}

Thus all these structural deformities in the kidney mass are obviously exhibitory of complex syndromes and altered capacity for renal excretion and osmoregulation and the present findings one in conformity with those of the above mention workers.

Intestine is an organ of digestion and absorption of food materials. In the present investigation the intestine showed acute level of damages in its cellular structure, particularly in the epithelial lining. The outermost serosal layer was broken at some position and the longitudinal muscles were loosely arranged, leaving small spaces (Fig. 3). On further exposure of the test specimens chronically, instances of damages were more apparent. The villi got reduced and were ruptured at some places (Fig. 4), jeopardising absorption.

Earlier also, several authors have noticed structural damages in the intestine of the fish exposed to the chemicals. There were some sort of structural changes in the intestinal tissue of some fish exposed to DDT, BHC, Dieldrin¹⁴ and effects of lindane BHC and Endrin on different organs of *Ophiocephalus punctatus*, *H. fossilis* *Trichogaster* sp. and *Barbus stigma*² Similar observations were also made by other workers.^{12, 15, 18, 21.}

Thus, the structural lesions in the form of dissolved epithelial lining in some position and ruptured vill in the present study are fully reflective of setback in digestive and absorptive ability of the intestine.

Hence taking all these facts into consideration, it is imperative to suggest discriminate use of the pesticides in the crop-fields, so as to save the fish wealth and awareness should be generated in the mass regarding conservation of environment and prevention of hazardous effects of the pollutants.

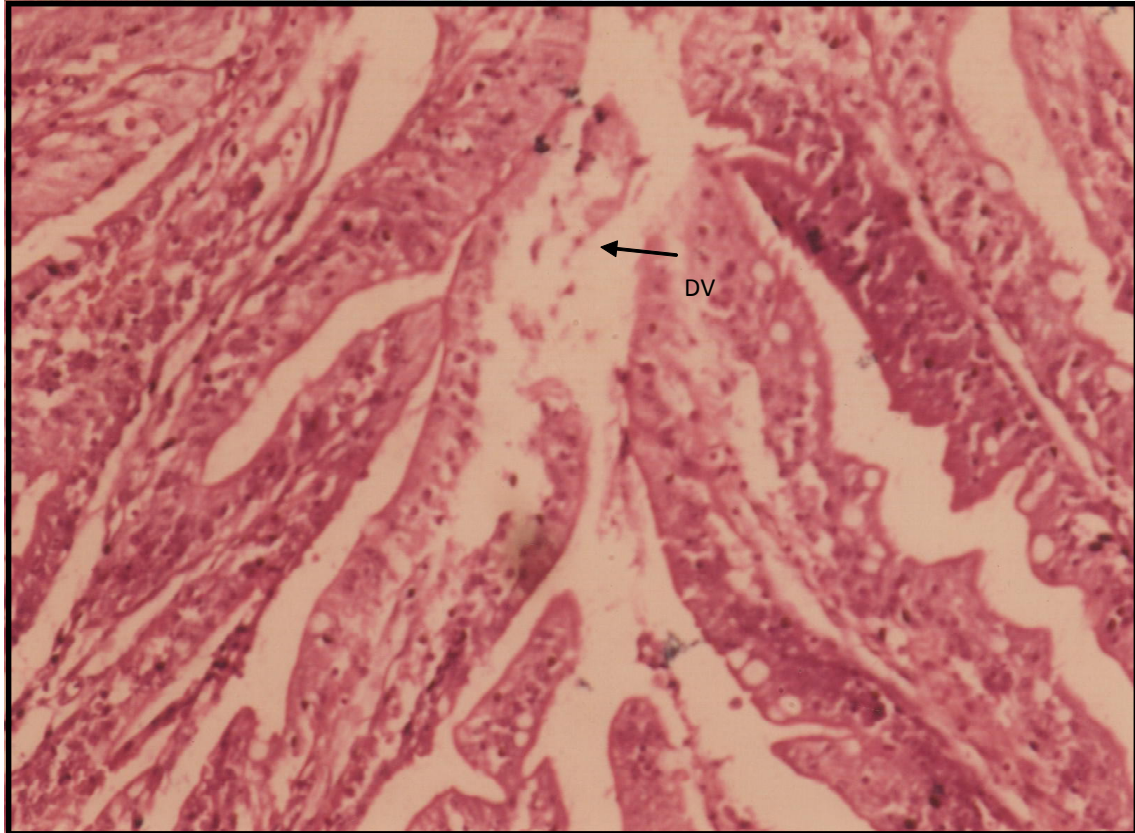


Fig. 4: Microphotograph of the section of intestine of bayrusil exposed *H. fossilis*, for 4 weeks showing damages. DV- Dissolved Villi. Haematoxylin – Eosin. X 400.

References

1. ALAM, M.D. NOOR (2014) studies on histopathological effects of an agro-chemical Ekalux EC 25 in the *Chironomus* larva. *Biospectra* **9** (1) : 75 - 78.
2. ANEES, M.A. (1975) Acute toxicity of four organo phosphorous insecticides to a fresh water teleost, *C. punctatus*. *Pakistan J. Zool.* **7** : 135 - 141
3. ANITA, SUSAN, SOBHA, T. K. AND TKAK, K.S. (2012) Toxicity and histopathological changes in three Indian major carps, *L. rohita* (Ham.) *C. catla* (Hom) and *Cirrhinus mrigala* (Ham) exposed to fenvalerate. *International J. Plant animal and Env. Sc.* **2** (1) : 18 - 32.
4. ANITA , SUSAN AND TKAK, K.S. (2003) Histopathological changes in vital tissues of the fish *Cirrhinus mrigala* exposed to fenvalerate. *Poll. Res.* **22** : 179 - 184.
5. DAS, S. AND SRIVASTAVA, G. J. (1980) Structural changes in the kidney of fresh water mud eel *Amphipnous cuchia* subjected to different osmotic conditions. *Archives d1 Anatomie Microscopique tome.* **69**(2) : 109 - 121
6. DAS B.K. AND MUKHERJEE S.C. (2000) Sublethal effects of quinalphos on selected blood parameters of *L. rohita* fingerling. *Assam. Fish Sc. P.* **3** : 225 - 235.
7. DEB, N. AND DAS, S (2014) Studies on histo-pathological changes in the gill tissue of *Channa*

- punctatus* exposed to the pesticide chlorpyrifos. Proc. 10^{1st} and Sc. cong P 169.
8. DIXIT, M., SRIVASTAVA, N. AND VERMA, S. (2013) Assessment of toxicity of an organophosphate on biochemical constituents of *Channa punctatus*. Proc. 83rd session NASI, P31.
 9. GANESHWADE, R.M. (2012) Effects of dimethoate on the level of cholesterol in fresh water *Puntius ticto* (Ham.) *Scientific Res. Reporter*, **2**(1) : 26 - 29.
 10. GOEL, K.A. AND GARG, V. (1977) Histopathological changes produced in the liver and kidney of *Channa punctatus* after chronic exposure to 2, 3 - 4 Triamino a20benzene. *Bull. Env. Contam. Toxicol* **25** : 330 - 334.
 11. GUPTA, A., SINGH, H.S. AND GUPTA, R.C.(2011) Biochemical alteration induced by lindane and chlorpyrifos pesticides in fresh water cat fish, *Clarius batrachus* *J. Exp. Zool, India*. **14**(1) : 149 - 152.
 12. JAUHAR, I. AND KULSHRESTHA, S.K.(1983) Histopathological changes induced by sub-lethal dose of endotolfan and carbaryl in the intestine of *Channa striatus*. *Ind. J. Zool.* **2**: 35 - 42.
 13. KUMAR, S. AND PANT, S.C. (1981) Histopathological effects of acutely toxic level of copper and zinc on gills, liver and kidney of *Puntius conchonus*. *Ind. J. Exp. Biol.* **19** : 191-194.
 14. MATHUR, D.S. (1962) Studies on histopathological changes induced by DDT in liver, kidney, intestine of certain fishes. *Experimentia* **180** : 506-509.
 15. NAGRAJAN, K. AND YUVARANI, K.E. (2006). Influence of neem oil on histology of gills, intestine and Retina of Indian major carp, *Labeo rohita*. *Nat-Env. Poll. Tech.* **5**(3) : 437-441.
 16. PATHAK, PRIYA AND SRIVASTAVA, A.K. (2007) Effects of detergent on the gills and kidney of *H. fossilis*. *Flora and Fauna* **13** (2) : 401 - 407.
 17. RANA AND RAIZADA (2000) Histological alterations induced by tannery and textile effluents in the kidney of *Labeo rohita*. *J. Env. Biol.* **21** (4) : 301-302.
 18. SAXENA, S. AND MATHUR, R. (1985) Histological changes in the intestine of fish *Channa striatus* exposed to Rogor. **5** : 42-45.
 19. SINGH, S.K., SINGH, S.K. AND YADAV, R.P. (2010) Toxicological and Prio-chemical alterations of cypermethrin agains fresh water teleost fish *Colisa fasciatus* at different season. *World J. Zool* **5** (1): 25-32)
 20. SHOBHARANI, A. AND NAGRAJU, T. (2007). Histological variation in fresh water teleost, *T. mossambicus* on exposure to arsenic. *Nat. Env Poll. Tech. Tech* **6** (4) : 637 - 642.
 21. SHUKLA, S.D., SUJATA, K. AND SAXENA, D.N. (2005) Effects of sublethal exposure an organophosphoruss pesticide, Nuvan on liver of cat fish, *C. batrachus*. *Nat. Env. Poll Tech.* **4** (3) : 447 - 452.
 22. TILAK, K. S., VEERAAIAH, K. AND YAQOBU, K. (2001) Studies on histopathological changes in the gill, liver and kidney of Ctenopharyngodon idellus exposed to technical fenvalerale and EC 29% *Polut. Res.* **20** : 387 - 393.
 23. TILAK, K.S., VEERAAIAH, K. AND RAO KOTESWARA, D.K. (2005b) Histological changes in the gill, liver, brain and kidney of the Indian major carp, *Cirrhinus mrigala* (Ham) exposed to chlorpyrifos. *Pollut. Res.* **24** : 101-111.
 24. VEL MURUGAN, K. (2012) Toxicity studies of combined pesticides in Indian major carps *Catla catla* and *Labeo rohita*. Ph.D. Thesis, Madras University, Chennai.
 25. VELMURUGAN, B., SELVANAYAGAM, M., CENZIZ, E.I. AND UNLU (2007) The effects of fenvalerate on different tissues of fresh water fish *Cirrhinus mrigala*, *J. Env. Sc. and H1th Part B* **42** : 157 - 163.